

The Anatomy and Function of the Normal Aortic Valve

Ferenc Puskas, MD, PhD
Assistant Professor
Division of Cardiothoracic Anesthesia
Department of Anesthesiology
University of Colorado at Denver and Health Sciences Center



Learning objectives

1. How does normal anatomy translates into echo views?
2. What surgeon needs to know?
3. Doppler interrogation of Aortic Valve (AoV)
4. Significance of Bicuspid AoV
5. Prosthetic alternatives
6. How much leak is too much?



Classification Used

ACC/AHA Practice Guidelines

ACC/AHA 2006 Guidelines for the Management of Patients With Valvular Heart Disease

A Report of the American College of Cardiology/American Heart Association Task Force on Practice Guidelines (Writing Committee to Revise the 1998 Guidelines for the Management of Patients With Valvular Heart Disease)
Developed in Collaboration With the Society of Cardiovascular Anesthesiologists (endorsements pending)

WRITING COMMITTEE MEMBERS

Robert O. Bonow, MD, FACC, FAHA, Chair; Blase A. Carabello, MD, FACC, FAHA; Kuni Chatterjee, MD, FACC; Antonio C. de Luna, Jr, MD, FACC, FAHA; David P. Faxon, MD, FACC, FAHA; Michael D. Freed, MD, FACC, FAHA; William H. Gersh, MD, FACC, FAHA; Bruce Wilensky Lyle, MD, FACC; Rick A. Nishimura, MD, FACC, FAHA; Patrick T. O'Gara, MD, FACC, FAHA; Robert A. O'Rourke, MD, MACC, FAHA; Catherine M. Otto, MD, FACC, FAHA; Pravin M. Shah, MD, MACC, FAHA; Jack S. Shanewise, MD*


TASK FORCE MEMBERS

Sibbey C. Smith, Jr, MD, FACC, FAHA, Chair; Alec K. Jacobs, MD, FACC, FAHA, Vice-Chair; Cynthia D. Adams, MSN, APRN-BC, FAHA; Jeffrey L. Anderson, MD, FACC, FAHA; Elliott M. Aronson, MD, FACC, FAHA; David P. Faxon, MD, FACC, FAHA; Valentin Fuster, MD, PhD, FACC, FAHA; Jonathan L. Halperin, MD, FACC, FAHA; Loren F. Heavicka, MD, FACC, FAHA; Sharon A. Hunt, MD, FACC, FAHA; Bruce W. Lytle, MD, FACC, FAHA; Rick Nishimura, MD, FACC, FAHA; Richard L. Page, MD, FACC, FAHA; Barbara Riggs, DMS, RN, FAHA




Goals of Aortic Valve (AoV) TEE exam

- Anatomy of valve, aortic root and left ventricle outflow tract (LVOT)
- Valvular and sub-valvular motion
- Relevant pathology
 - Chamber size
 - Wall thickness
 - LV function




Purpose of Intraoperative AoV TEE exam


- To refine and confirm preoperative diagnosis
- Etiology and severity of AoV disease
- Sizing of Aortic Annulus
- Surgical Success – small annulus, surgeon can be prepared for other alternatives (root enlargement, or stentless valve implantation)

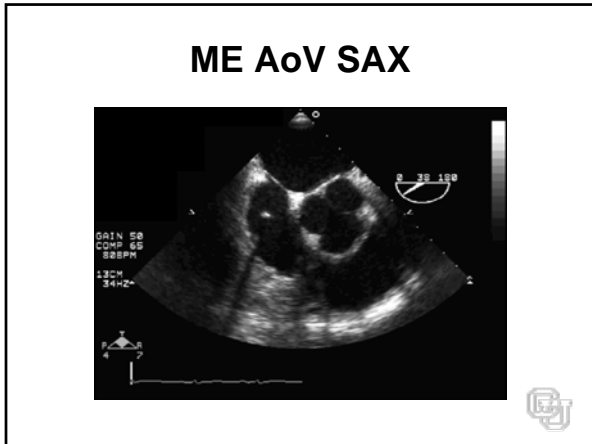


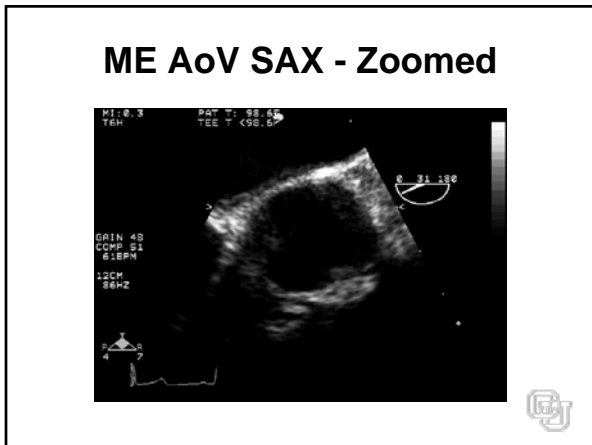20 cross-sectional views composing the recommended comprehensive TEE examination

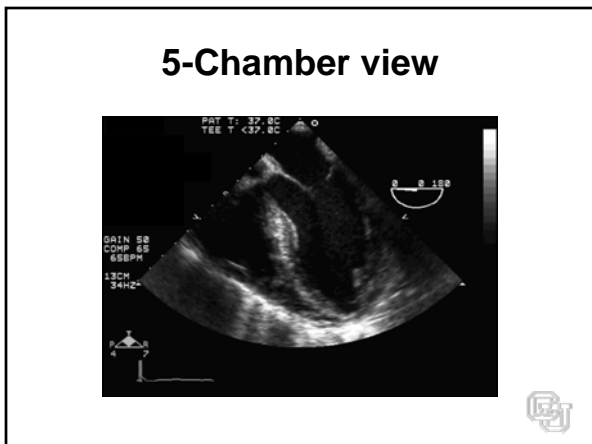


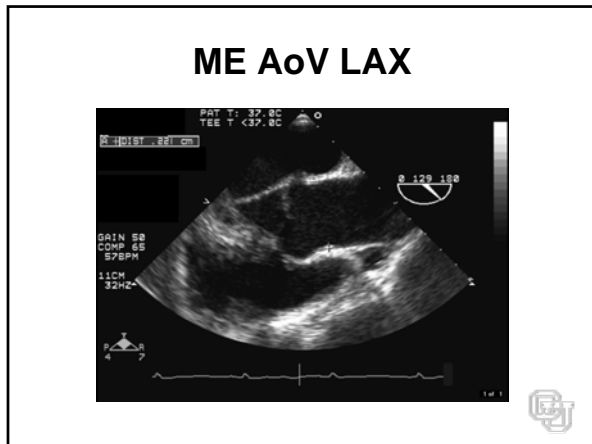
Shanewise, J. S. et al. Anesth Analg 1999;89:870

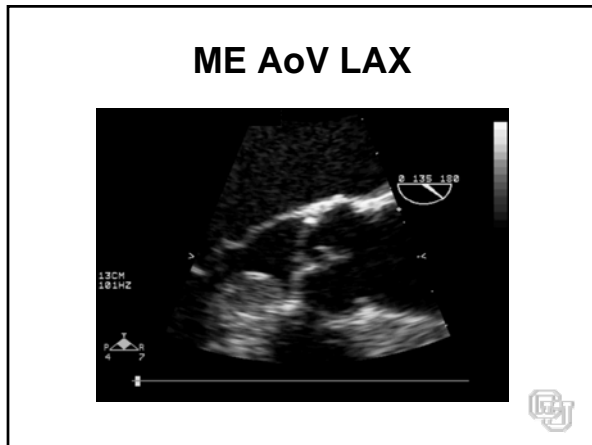


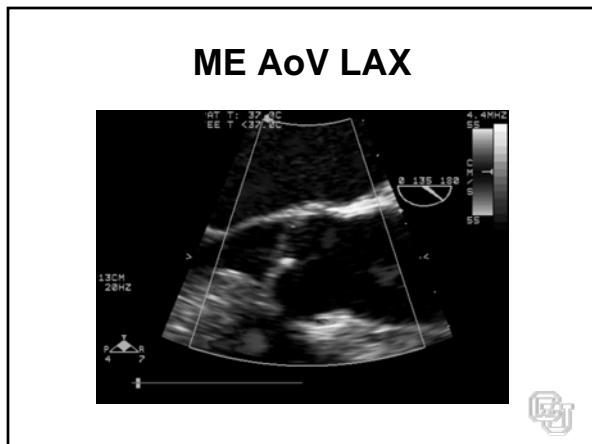










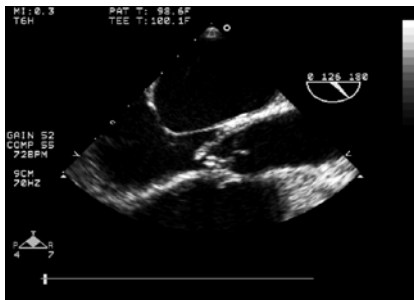

Papillary fibroelastomas

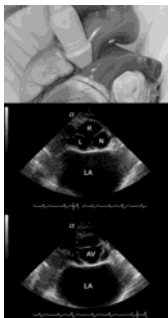
- Aortic Valve Cusps (44.5%)
- Either side of AoV (more commonly aortic side)
- Short pedicle, multiple
- Lambl's excrescences:
 - Degenerative in origin
 - Edge of AoV along the coaptation point
- They may cause angina, infarction or embolism



AoV Endocarditis



Epiaortic views



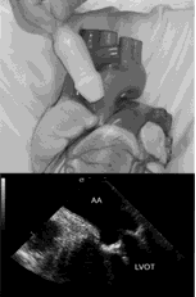
- Midesophageal aortic valve short-axis equivalent view

Eltzschig et al. J Cardiothorac Vasc Anesth. 2003 Aug;17(4):422-9.




Epiaortic views


- Aortic Root View



Eitzschig et al. J Cardiothorac Vasc Anesth. 2003 Aug;17(4):422-9.




AoV short axis with color




Aortic Valve Doppler Imaging

- Continuous wave Doppler (CWD): Transvalvular velocities with modified Bernoulli equation are converted to peak and mean pressure gradients
- Pulsed wave Doppler (PWD): LVOT gradient
- Deep TG LAX view, 0-120 degrees




Aortic Valve Doppler Imaging

- Modified Bernoulli equation
 - ✓ $\Delta P = 4V^2$
 - Ignored
 - Convective acceleration
 - Flow acceleration
 - Viscous force
- Peak gradient (ΔP_{max}) is an instantaneous peak pressure gradient
- Cath Lab measures 'peak to peak' gradient that from physiological standpoint does not exist, it is always lower than the echocardiographic peak instantaneous gradient




Aortic velocity and gradient

Severity of AS	Jet velocity m/s	Mean Gradient mmHg
Normal		
Mild	< 3.0	< 25
Moderate	3.0 – 4.0	25 – 40
Severe	> 4.0	> 40




Estimation of Aortic Valve Area Using the Continuity Equation

- Assumption: Orifice is circular
 - $Area_{LVOT} = 0.785 \times diameter^2$
- Rearranged Continuity equation
 - $AVA = Area_{LVOT} \times TVI_{LVOT} / TVI_{AoV}$
- All cm/s!



Bernoulli and Continuity Equation Pitfalls


- LVOT diameter measurement error (squared)
- Subaortic obstruction (obscures LVOT VTI)
- Non-sinus rhythm
- Incorrect peak AoV velocity (MR)
- Incorrect angle: Doppler equation, importance of echo beam in relation to blood flow



Doppler equation, % error from angle of incidence


- $\Delta f = 2F_t \times v \times \cos \theta / c$
 - ✓ Δf = Doppler shift
 - ✓ F_t = Frequency transmitted
 - ✓ v = velocity
 - ✓ $\cos \theta$ = cos of blood flow and beam angle
 - ✓ c = speed of sound (1560 m/sec)

Angle °	0	10	20	30	45	60
% Error	0	2	7	14	30	50




Bicuspid Aortic Valve

- Bicuspid aortic valve (BAV) occurs in approximately 1% to 2% of the population
- Most BAV have 3 aortic sinuses and the larger one of the two cusps has a raphe instead of a commissure
- The right coronary artery is usually non-dominant and small




Bicuspid Aortic Valve

- Aortic Stenosis
 - 5th and 6th decade
- Aortic regurgitation
 - Isolated
 - Associated with
 - With root dilatation/aneurysm
 - Endocarditis




Bicuspid Aortic Valve and Ascending Aorta Dilatation

- 44% in normally functioning BAV
- 50-64% with various degrees of valve diseases
- Aortic Dissection - 5%
- Aortic wall medial abnormalities
 - Genetic weakness resembling cystic medial necrosis (it co-exist (co-inherited) with BAV)






Choosing Type of Valve Operation

- Surgeon's experience and preference
- Repairable? → Repair
- Contraindication to Coumadin?
- Patient factors
 - Age
 - Likely life span
 - Heart rhythm
 - Other valves?
 - Future Pregnancy?
 - Patient preference
 - Size of annulus




Prosthetic Valves

- Mechanical Valves
 - Single Tilting disk 
 - Medtronic-Hall – Medtronic® (central regurgitant jet)
 - Bjork-Shiley (no longer available)
 - Double Tilting Disk
 - St. Jude – St. Jude Medical® (most widely used)
 - Carbomedics – Sulzer Carbomedics®



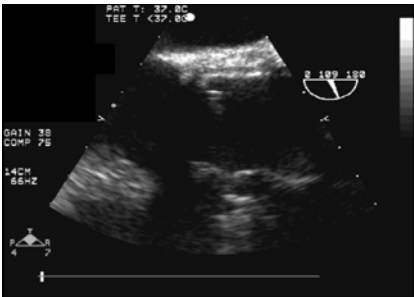
Bjork-Shiley




Technical details from the echocardiogram:
PAT T: 37.80
TEE T: <37.80
GAIN 38
COMP 75
14CM
95HZ

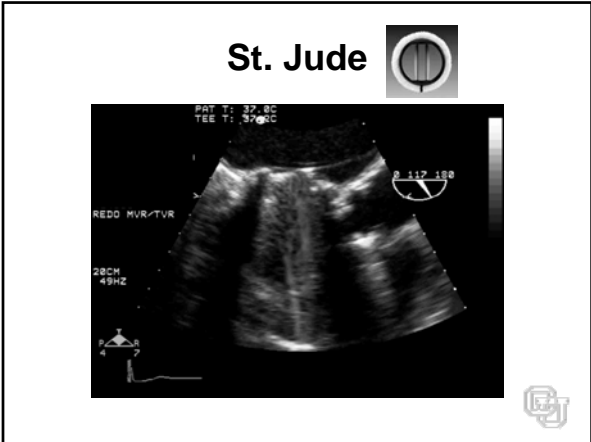


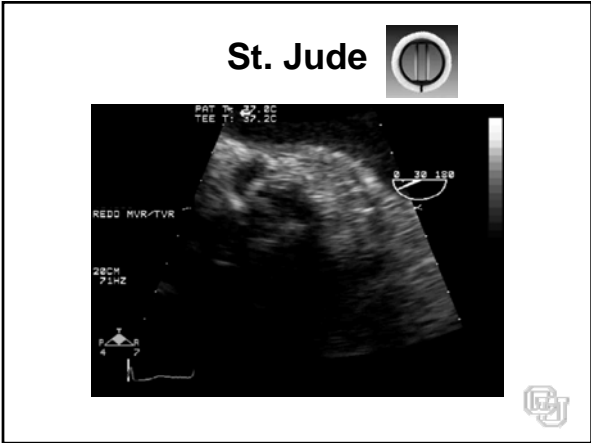
Bjork-Shiley




Technical details from the echocardiogram:
PAT T: 37.80
TEE T: <37.80
GAIN 38
COMP 75
14CM
66HZ









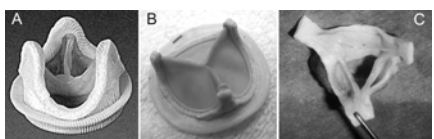


Prosthetic Valves


- Tissue Valves
 - Stented Bioprosthesis
 - Hancock – Medtronic®
 - Carpentier-Edwards – Baxter Healthcare®




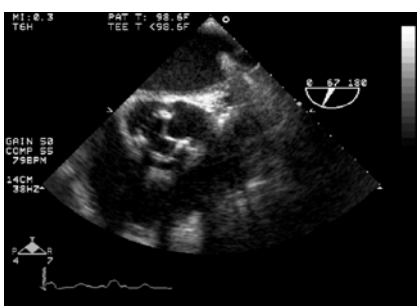
Images of a porcine bioprosthetic valve xenograft (A), bovine pericardial valve (B), and a human aortic valve allograft (C), also called a homograft



Vesely, I. Circ Res 2005;97:743-755



Tissue Valve

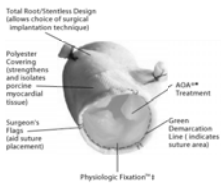

Stentless Aortic Bioprostheses

- St. Jude Medical Toronto SPV (porcine aortic root) – only subcoronary implant
- Medtronic Freestyle (porcine aortic root)
- Edwards Lifesciences Prima Plus
- CryoLife O'Brien, AorTech Freeseewn Porcine Elan, Shelhigh No-React, Biocor PSB/SJM, Sorin Pericarbon



Medtronic Aortic Root 'Freestyle' bioprosthesis

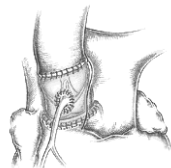


- Absence of a stent a sewing ring leaves more room for blood flow
- In many cases a Freestyle valve that is one or two size larger can be implanted



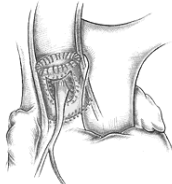
Full root technique

- Sinus of Valsalva and diseased aorta excised

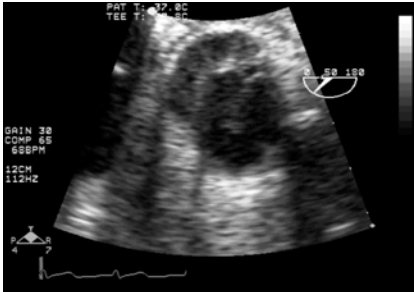


Root inclusion technique

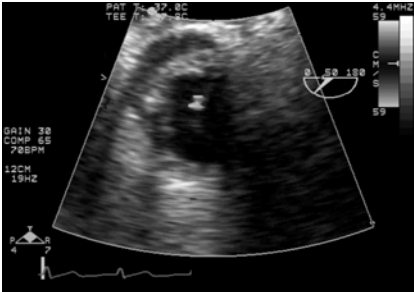
- After performing an aortotomy and removing diseased aortic leaflets, the bioprosthesis is placed inside the native aorta



Freestyle with Root Inclusion

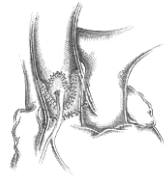

Freestyle with Root Inclusion

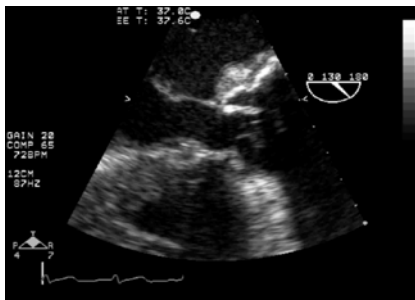


Complete subcoronary technique

- After performing aortotomy and removing the aortic valve leaflets, the scalloped valve is placed inside the native aorta. Clearance for the coronary ostia is allowed by scalloping all three sinuses of the bioprosthesis.



Freestyle AV LAX



Aortic Paraprosthetic Leak

- 85 patients after AVR followed for 5 years
- Paraprosthetic Leaks were detected in 47% of the patients, 90% were small and remained unchanged
- New sudden sever paravalvular regurgitation (3 patients) was associated with endocarditis (2) and prosthetic valvular failure (1)

Rallidis et al. Am Heart j. 1999; 138: 351-7.



**Intraoperative Aortic
Regurgitation with Stentless
Valves**

- 96 patients with Freestyle bioprosthesis
- Post-pump minimal to mild regurgitation was present in 52% of the patients
- One year no patient had more than mild regurgitation
- Aortic regurgitation completely resolved in 62% with post-pump regurgitation
- Conclusion: Minimal to mild regurgitation is common and does not predict clinically significant progression

Bach et al. Sem Thorac Cardiovasc Surg. 1999. 11(4S1):88-92



**The Anatomy and Function
of the Normal Aortic Valve**

Thank you!