
FIBEROPTIC AIRWAY MANAGEMENT

Geoffrey Lane, MB, FRCA
The Children's Hospital
Denver

TOPICS

1. Selection and care of equipment

- Choice of fiberoptic endoscope
- Video systems
- Avoiding damage
- Cleaning and sterilization

2. Navigation skills

- Introduction
- Rotation
- Flexion (control lever)
- Anatomic deflection and direction

3. Decisions

- Awake vs. asleep
- Oral vs. nasal
- Nasal: tube first or scope first?

4. Problem solving

- The tongue is in the way!
- The larynx is hidden because the epiglottis is stuck to the back of the pharynx!
- Laryngeal impaction and the S bend!
- The scope is always misting up!
- The view seems all wrong (upside down?)

5. Advanced applications

- Pediatric intubations
- Single lung ventilation – double lumen tubes and blockers.
- Intubation through the LMA.
- Intra-operative diagnosis of ventilation problems
- The extreme airway

Section 1: Selection and care of equipment

Choice of fiberoptic endoscope.

Unless you are able to borrow a 'scope, selecting a suitable system is often the first and most important decision in developing a fiberoptic intubation program.

Desirable features include:

- Insertion tube length 50 – 60 cm
- Appropriate diameter -for ETT's likely to be used (including double lumen tubes)
- Flexible tip (cannot maneuver without it)
- Suction channel – useful but not essential - for local anesthetics, guide wires etc.
- Ease of cleaning and sterilization
- Compatibility with light sources and video equipment.
- Digital 'scopes have much better resolution, and should be less easily damaged
- Durability, Durability Durability!!!
- Price

The scopes that are designed for intubation are usually cheaper (approximately \$1000) than corresponding diagnostic bronchoscopes, and have a thickened sheath covering the insertion tube to protect them from abuse by anesthesiologists (other than you, of course!) They lack some of the electronic photography exposure features of diagnostic scopes, but can still be used with a video camera, and are generally the best choice for anesthesiologists.

The basic “intubation” scopes represent a compromise in regard to diameter. As the diameter is reduced, the scope can be introduced through smaller endotracheal tubes and thus extended to pediatric use, and for examining placement of double lumen tubes. The disadvantage with smaller scopes is that when passed through large adult sized endotracheal tubes, there is a greater tendency for the tube to become caught on the laryngeal inlet. This can be very frustrating, but there are several methods to avoid or manage this problem (see page 9.)

Ultra thin pediatric scopes are available and can be used inside 3.0 mm tubes. They are soft, flimsy and more difficult to use. Though valuable for pediatric use, they are not suitable for routine intubations with endotracheal tubes larger than 4.5 mm. Ultra thin scopes may be required when examining the placement of small double lumen tubes and blockers.

Price is obviously a major consideration, but repairs are so expensive that **durability** is even more important. We have found that the Olympus scopes withstand punishment well, and are still using a 20 year old LF1 that has only been repaired twice despite frequent (ab)use by all-comers.

Storz has new scopes with good optical resolution. They are available with an integral camera head mounted on the scope, the video output produces an excellent large image compared with older systems.

Olympus has a new range of digital scopes with a video chip mounted on the distal end of the scope. This improves the resolution dramatically, and the scopes are less prone to damage because the image is transmitted electrically rather than by fragile glass fibers.

Video Systems

The purchase of a camera and video system significantly enhances a fiberoptic intubation system. (When did you last see your friendly orthopod doing an arthroscopy without an expensive video tower?)

When learning or teaching, technical maneuvers can be observed on the screen and corrected easily, whereas the novice using the eyepiece can only be guided by clinical evidence of success or failure. The video system is also valuable in difficult airways, when an assistant is needed to retract the tongue and soft tissues, or to help thread a guide wire through the scope. When the assistant can see the results of his efforts on the screen, the assistance is more effective.

Video use also has psychological advantages by involving the OR team. When the surgeons and OR nurses can share your fiberoptic exploits on the screen, they are much more likely to offer support and encouragement than when your endeavors are seen only as an irritating delay before they can have their fun!

Avoiding damage

Success in fiberoptic intubation requires continued access to a satisfactory fiberoptic system. There are several easy but expensive ways to damage the scope and render it unusable. We teach our staff and residents this mnemonic:

“Please Don’t Damage This Thin Scope!”

Petroleum based lubricants such as Vaseline and lacrilube can penetrate the cover of the scope and cause separation of the fibers; use aqueous lubricants such as KY jelly or silicone.

Drawer Don't leave the scope in the drawer of the endoscopy cart while connected to the light source; shutting the drawer will crush the glass fibers.

Door Don't leave the scope plugged into the light source when removing the endoscopy cart from the room - the light cable can easily be smashed on the door frame!

Teeth A good bite can crush the scope - if the patient is awake, protect the scope with a bite block or airway.

Tube Advancing the tube down over the scope while bending the tip may damage the vulnerable, flexible tip section - always remove pressure from the control lever and keep the tip straight while advancing the tube.

S - Bend The scope can be forced into an S-bend when the tube tries to continue passing down the esophagus while the scope remains in the trachea. If you encounter resistance when advancing the scope through the larynx, **DO NOT FORCE IT!** Try rotating the tube 90 or 180 degrees, or use an introducer.(see page 9)

Cleaning and sterilization

There are several reports of disease transmission attributable to faulty preparation of endoscopes, including episodes of hepatitis, tuberculosis and more recently, pseudomonas. Ease of cleaning and sterilization is therefore essential.

Most modern scopes may be immersed in cleaning fluids or be subjected to gas sterilization. With increasing environmental concerns regarding use of ethylene oxide, we have found the use of automated fluid sterilization machines (e.g. the Steris system) to be efficient and easy to use.

Section 2: Navigation Skills

Introduction

The simplest approach to intubation with a fiberscope is to point the scope so that the target (larynx) is in view, and then try to advance the scope towards the target or through it. This "point and shoot" approach works in many adult patients, and is the method most people use initially. The skillful operator develops more advanced navigation skills with experience, intuition and manual dexterity. These skills will be demonstrated in the workshops, but understanding the basic principles can enable the student to advance more quickly.

There are three different types of maneuvers that can be used to control the scope; the expert is able to advance and navigate the scope smoothly through the airway by combining these controls effortlessly – just like a teenager operating a video game!

(1) Rotation

The image transmission pathway in the insertion tube of the fiberscope is constructed of bundles of parallel glass fibers. The 12 o'clock position is marked by an indent or black triangle to assist in orientation. Rotating the scope through 90 degrees will cause the 12 o'clock marker to rotate correspondingly, but so long as the observer is viewing the target through the eyepiece, the target will not change position. (The image will be carried through different fibers, but the spatial relations between target and observer are the same.)

A camera placed on the eyepiece will rotate with the scope, so that the indent will remain in the 12 o'clock position if the scope is rotated 90 degrees, and on a video screen the image of the target will now appear rotated.

When using rotation to control the scope, it is easier for novices to keep the scope relatively straight by keeping both hands as far apart as possible, otherwise a big loop may develop, and the tip may flex in unexpected directions.

(2) Flexion (control lever)

The distal tip section of the scope bends up or down with light pressure on the control lever. The flexible (or bending) part of the scope is short, and flexing it does not necessarily control the remainder of the insertion tube. It is also the most fragile part of the scope, since it has to be covered with a thin, flexible covering, and can be damaged by excessive force and by sliding the endotracheal tube down and into the flexed tip.

Since intubation scopes are only flexible in one plane, it may be necessary to combine flexion and rotation when navigating difficult or 'tortuous' airways.

(3) Anatomic deflection and direction

The greater part of the length of the insertion tube is not controlled directly by the control lever, but responds indirectly to pressure against anatomic features as the scope is advanced. The operator can aim the scope as it enters the mouth or nose, and by directing it against structures (e.g. the palate), can encourage the scope to assume an optimum trajectory. This type of control is demonstrated more easily than it can be described, but should be mastered if the operator is to exploit the full potentials of fiberoptic intubation.

The chances of success improve when the endoscopist has good manual control of the scope and can keep the scope in the mid-line all the way to the trachea. Recognition of the mid-line landmarks facilitates navigation, for oral intubation they include:

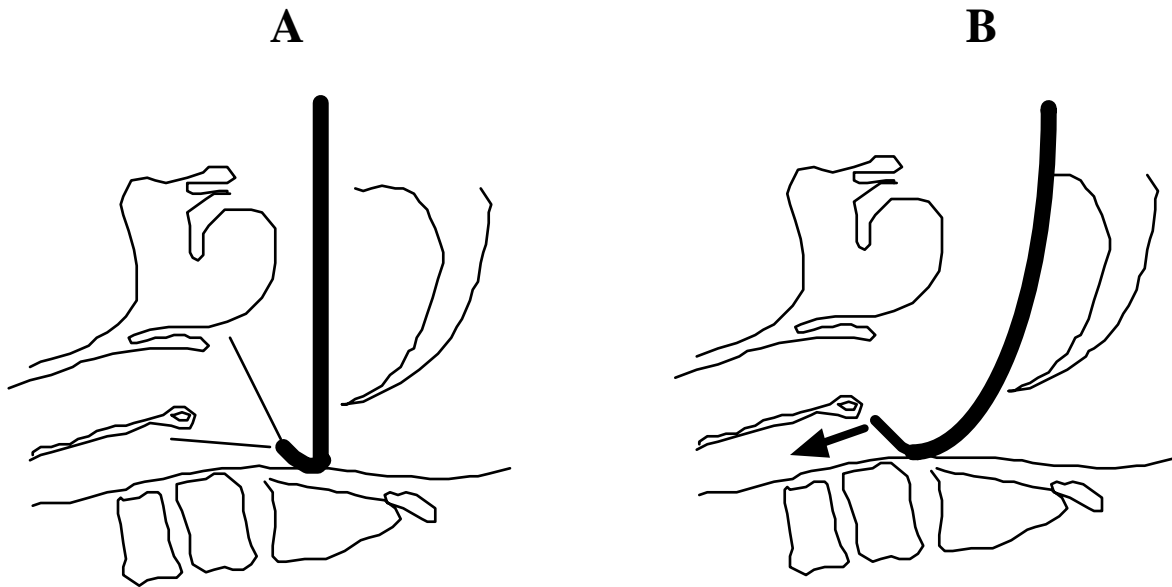
Posterior:

- Raphe (fine white line) in palate, that leads to the -
- Uvula

Anterior

- Furrow, or groove, down mid-line of tongue, leading to the -
- Epiglottis

Failure to understand this principle of navigation is the reason for the scope passing into the esophagus even though the operator may have visualized the larynx clearly. The problem occurs during oral intubation when the scope is introduced directly backwards (see below, **A**) and the tip is flexed acutely upwards to see the cords. As the scope is pushed down the airway, the tip may still lie behind the arytenoids so that the scope enters the esophagus rather than the larynx (**B**.) This problem is more likely to occur in small patients; adults tend to be more forgiving because the larger distances involved allow the scope to bend more towards the intended direction.

**Section 3: Decisions****Awake vs. Asleep**

The difficult adult airway is usually managed safely and more easily in the awake patient, using good topical anesthesia, with judicious sedation.

Children do not always cooperate well under topical anesthesia, and sedation for difficult pediatric airways can quickly lead to obstruction and hypoxia. I generally recommend an

inhalation anesthetic for children between 12 months and 10 years, but the ability to maintain an adequate airway using a chin thrust maneuver is essential, and relaxants should be avoided.

There are many ways to achieve good topical anesthesia. I prefer to use viscous lidocaine first, and will then inject lidocaine through the suction channel of the scope into the larynx. Inhaling a nebulized solution of lidocaine is also effective if administered until the airway is anesthetized. It is easy to exceed therapeutic doses of local anesthetics and cause toxicity especially in smaller patients; the safe dose should be estimated before use.

Oral vs. Nasal

Nasal intubation is technically easier than oral intubation because the intranasal structures support the scope and facilitate a smooth advance. The convexity of the cervical spine helps to direct the scope forwards and away from the posterior pharyngeal wall towards the laryngeal inlet.

There are situations where oral intubation may be preferred for surgical access, e.g. for cleft palate surgery. There is also a risk of bleeding with nasal intubation despite the use of vasoconstrictors, and is of sufficient concern in the most precarious airways that oral intubation may be the first choice.

Oral intubation requires more dexterity and skill in keeping the scope towards the mid-line, and in small patients it may even be necessary to press the scope against the palate to achieve enough curvature to enter the larynx.

Nasal: tube first or scope first?

Passing the endotracheal tube through the nose before advancing the scope may appear easier than threading the scope through the nose first, but can cause severe bleeding and jeopardize the intubation. The tube is stiff enough to penetrate the posterior wall of the pharynx, causing a false passage, or it may perform a partial adenoidectomy.

With a little practice, the scope can be directed through the nose without tearing the mucosa and adenoids, and it will make the turn at the back of the nose more easily.

Section 4: Problem Solving

The tongue is in the way!

The tongue often presents a major visual obstruction when intubating difficult airways, especially when the patient is unconscious.

Maneuvers to pull it forwards include use of a chin thrust, pulling the tongue out of the mouth with a dry sponge, and mechanical devices. Of these, I find that a narrow, malleable surgical retractor can be shaped and used successfully in some of the most difficult pediatric airways.

The larynx is hidden, because the epiglottis is touching the back of the pharynx!

This is what difficult airways are all about! In the awake patient, a deep breath will often lift the tip of the epiglottis off the posterior wall of the pharynx enough to allow the scope to be advanced.

The anesthetized patient is more of a challenge. A chin thrust by an assistant is often sufficient, but in extreme airways, it may be necessary to pull the tongue forwards using a dry sponge, or by using a malleable ribbon retractor bent to an appropriate shape.

Laryngeal impaction and the S-Bend – or- ‘the tube won’t go down the larynx!’

Very frustrating! This happens when the tube is much wider than the scope, and the tip of the tube impacts on the ary-epiglottic folds or on the arytenoids. Once this has occurred, the situation can often be resolved by withdrawing the tube a short distance and rotating it 90 or 180 degrees. The tube may then be advanced, and the tip should lie above the scope so that it passes the anterior commissure, without impacting the ary-epiglottic folds. The problem may be anticipated and avoided by several strategies:

1. Selecting a fiberscope whose diameter is as close to that of the endotracheal tube as possible will usually prevent the problem.
2. The new endotracheal tubes manufactured by Parker Medical Systems have a special tip that bends inwards to reduce trauma to the mucosa as the tube is advanced. The tip will remain in touch with a fiberscope passing through the laryngeal inlet and should avoid the “S-bend problem.”
3. An introducer can be placed between the fiberscope and the endotracheal tube just as we use a dilator or introducer between the guide wire and catheter/sheath during central venous cannulation.
Suitable devices include either a straight chest tube, or a small uncuffed endotracheal tube. The chest tube has the advantage of being longer; an uncuffed endotracheal tube is so short that the larger ETT may need to be shortened from 4 to 6 cms.

The appropriate sizes when using an Olympus LF2 scope are:

Outer ETT	Introducer:	Introducer:
-----------	-------------	-------------

(mm, ID)	A: Chest Tube	B: Uncuffed ETT	(length)	(ext diam)
7.5 mm	-	5.0 mm	24.5 cm	6.9 mm
8.0 mm	-	5.5 mm	27.5 cm	7.5 mm
8.5 mm	24 FG	6.0 mm	28.5 cm	8.2 mm
9.0 mm	24 FG	6.0 mm	28.5 cm	8.2 mm
9.5 mm	28 FG	6.5 mm	29 cm	8.9 mm

The scope is always misting up!

This problem is usually caused by allowing the tip of the scope to touch the mucosa. Careful navigation, keeping to the lumen of the airway, will eliminate this problem, but if it does occur, clean the end with an alcohol wipe. When using a video camera, a 'white out' is a warning that you are almost touching the mucosa - retreat and find the lumen before advancing!

Section 5: Advanced Applications

Pediatric intubations

1. **Guide wire method:** a regular intubation scope can be used to intubate infants (when an ultra thin scope is not available,) by threading a long (125 cms) guide wire through the suction channel into the trachea. Suitable J wires can be ordered (or "appropriated" from the cath. lab in an emergency), a 0.032" to 0.036" diameter wire is usually appropriate. The scope is then withdrawn over the wire, and an appropriate ETT advanced, using a small suction catheter inside the ETT to facilitate the advance.
2. **Ultra thin fiberscopes:** Pediatric fiberscopes such as the Olympus LFP, with a 2.8 mm diameter that fits inside 3.0 mm ETT's have extended routine fiberoptic intubation abilities to neonates. These scopes are much softer and are more difficult to control, but can be life saving.

Single lung ventilation - double lumen tubes and blockers

Fiberoptic scopes may be used to place and verify correct positioning of double lumen tubes. Confusion regarding which lumen to use is simplified if you remember that the scope may be used for two distinct purposes.

First, the scope can be inserted through the *distal, bronchial* lumen to direct the tube from the lower trachea into the selected mainstem bronchus.

Second, it can be used to confirm and adjust the position of the bronchial cuff, to ensure that the endobronchial cuff is just inside the bronchus, and that when inflated, the cuff does not extend beyond the carina to obstruct the trachea.

The practical sequence is therefore:

1. Place the tube into the trachea by conventional direct laryngoscopy.
2. Advance the tube into the main stem bronchus, either directly - by simply pushing and turning it in the traditional manner, or endoscopically - by inserting the scope through the *bronchial lumen* and then into the selected main bronchus.
3. The position of the bronchial cuff in relation to the carina is inspected by inserting the scope through the **tracheal** lumen. The scope should emerge just above the carina, and the bronchial cuff should be entirely within the bronchus - to avoid obstruction of the trachea. Correct inflation of the cuff can be observed directly to avoid hyperinflation.

Bronchial blockers can be used in smaller patients. A 5FG Fogarty embolectomy catheter has been used for pediatric patients. The catheter should be placed in the trachea prior to intubation, (a 45° bend facilitates directing it to the desired bronchus.) The scope is then passed through the ETT and positioned just above the carina to observe and adjust the position of the balloon, which is then carefully inflated with saline until the bronchus is occluded, using the minimum volume necessary. There are reports of bronchial rupture from over-inflation.

Intubation via the LMA

A fiberscope can be placed through an LMA (or other supraglottic airway) to facilitate intubation in patients who cannot be intubated directly for anatomical or neurologic reasons. The Fastrach LMA can serve as a conduit for intubation without using a fiberscope, but is not available for small children.

When using a fiberscope through the LMA, the ETT can be passed over the scope and into the trachea, but the ETT is usually too short to allow the LMA to be removed. If this is necessary, then a second smaller ETT can be wedged inside the proximal end of the first ETT until the LMA is removed. Alternatively, a long guide wire can be placed through the suction channel of the fiberscope. The LMA is then withdrawn, and an appropriate size ETT is then advanced over the wire, using a suction catheter inside the ETT to support the wire and facilitate passage through the glottis.

Intra-operative diagnosis of ventilation problems.

The fiberoptic scope can be an asset in the diagnosis and management of a variety of intra-operative ventilation problems, for example:

1. The surgeon claims the left lung is not moving as you come off by-pass. You can try pulling the tube back - but risk extubating the patient. Passing the scope down the tube allows you to confirm the position (or improve it) and turns your attention to shifting the mucous plug obstructing the left bronchus.
2. Difficult ventilation in the neurosurgical patient in the sphinx or prone position: the tube may be kinked, blocked or positioned incorrectly - use of the scope may facilitate resolution of the problem.
3. Reintubation. The scope may be used to reintubate either electively, or sometimes in emergency situations (e.g. the infant accidentally extubated coming off by-pass, when direct laryngoscopy interferes with the aortic cannula)

Suggested Reading

1. Biebuyck JF: Management of the difficult adult airway. *Anesthesiology* 75:1087- 1110, 1990
2. Ovassapian, A: *Fiberoptic Endoscopy and the Difficult Airway* (2nd Edn); 1996, Lippincott Williams & Wilkins.